
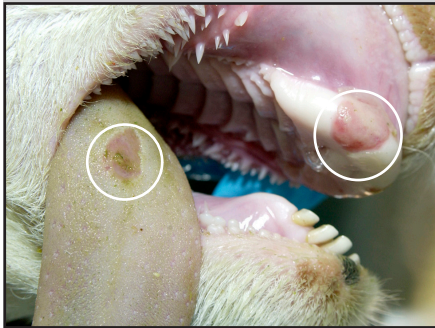






# FOOT-AND-MOUTH DISEASE IN SHEEP

## PROGRESSION OF LESIONS

Foot-and-mouth disease (FMD) lesions may be mild or not apparent in adult sheep but can also be severe like in cattle or pigs. Vesicles, ulcers, and erosions in and around the coronary band, mouth, and nose may be seen. These lesions cause clinical signs like lameness. Fever and reduced feed intake can happen in sheep infected with FMD. Infected young lambs sometimes die suddenly due to heart disease. The following lesion ages are approximate.

	CORONARY BAND	DENTAL PAD, TONGUE	NASAL MUCOSA
EARLY LESION (1-5 DAYS)	 <p>Blanching of the coronary band</p>	 <p>Focal erosion of the dental pad and tongue</p>	 <p>Focal erosion of the nasal mucosa</p>
LATE LESION (5-7 DAYS)	 <p>Erosion of the coronary band with fibrin deposition</p>	 <p>Multifocal healing erosions on the dental pad</p>	 <p>Erosion on the nasal mucosa with fibrin deposition</p>

### If you suspect a Foreign Animal Disease

Call your State Animal Health Official (SAHO) or Area Veterinarian-In-Charge (AVIC) to report your concerns. If you do not have access to the contact information of the SAHO or the AVIC at your location, you can call 1-866-536-7593, to reach the office of the AVIC for your state. You can also call the USDA APHIS Veterinary Services National Center for Animal Health Emergency Management at 800-940-6524 (24 hours) for assistance.

**Photo Credit:** USDA APHIS Foreign Animal Disease Diagnostic Laboratory and the U.S. Department of Homeland Security ARSC AFFS Visual Information Service at Plum Island Animal Disease Center.